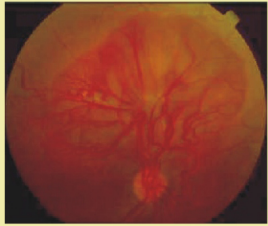
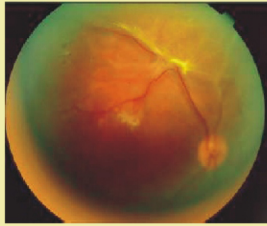


## TREATMENT OF PROLIFERATIVE DIABETIC RETINOPATHY:-

It consists of 2-3 sittings of laser treatment to entire retina except the optic disk and macula. Also called Pan Retinal Photocoagulation (PRP)



**PRE LASER TREATMENT**  
Shows Florid new vessels above Optic disc before laser treatment



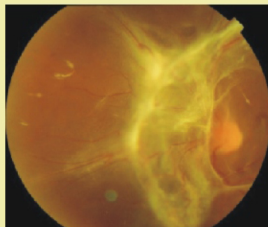
**POST LASER TREATMENT**  
Shows regressed new vessels after laser treatment

## ADVANCED PROLIFERATIVE DIABETIC RETINOPATHY:-

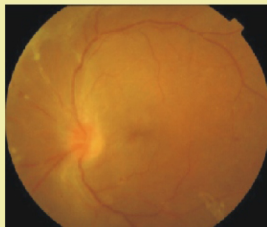
Some patients present at this stage, some patients worsen despite adequate laser treatment and may have vitreous hemorrhage, retinal detachment and Neovascular Glaucoma. These patients may have very poor vision.

### TREATMENT:-

PRP laser. if possible and Vitreous surgery to remove scar tissue. Usually, the results are encouraging.



**BEFORE SURGERY**  
Extensive scar tissue on retina with detachment



**AFTER SURGERY**  
All scar tissue removed & No detachment

## WHO IS AT RISK OF DEVELOPING DIABETIC RETINOPATHY?

Diabetic Retinopathy is the most leading cause of preventable blindness after cataract. Risk Factors are :

- 1.)Duration of diabetes: Longer the duration, more the risk.
- 2.)Type of control of diabetes.
- 3.)High blood pressure and smoking.

## WHAT HAPPENS DURING YOUR EXAMINATION?

Your pupils are dilated with eye drops and retina is examined by special equipments like Indirect Ophthalmoscope and Slit Lamp Bio

## IMPORTANT THINGS TO PREVENT BLINDNESS IF YOU ARE DIABETIC:-

- 1.) Strict control of blood sugar, blood pressure and cholesterol.
- 2.) Regular visits for checking retina, even if you do not have problem with your vision.
- 3.) Timely treatment of lasers or vitreous surgery to prevent blindness.

**ace** | **Advanced Centre  
for Eyecare**  
Superspeciality Eye Hospital

### **Dr. Priyanka Shah**

MBBS, FCPS, MS, FVRS  
Vitreous Retinal Surgeon & ROP Consultant

### **Dr. Akshat Shah**

(MBBS, DO, DNB, FCRS)  
Cornea, Cataract & Refractive Surgeon  
TEH, LVPEI (HYD), BPEI (USA), WFU (USA)

# DIABETIC RETINOPATHY

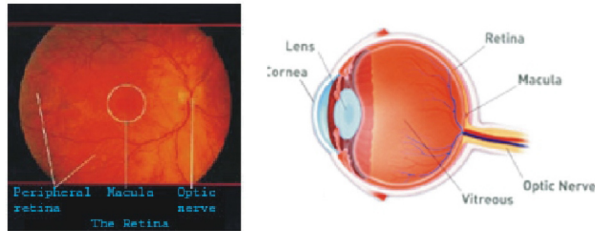


**ace** | **Advanced Centre  
for Eyecare**  
Superspeciality Eye Hospital

Specialist in Diseases of Vitreous & Retina  
Lasers & Ultra Sonography & Microsurgery of Eye

**WHAT IS RETINA?**

The retina is like the film of a camera. It is the seeing tissue. It has two parts, the Peripheral Retina & Macula (Central Retina). Macula is responsible for clarity and quality of vision. Peripheral Retina enables us to have panoramic view. Macula has a large



The Retina panoramic view

Cut section of the eye

**WHAT IS DIABETIC RETINOPATHY?**

Diabetes Mellitus is a disorder of sugar/ glucose metabolism in the human body in which the body cannot utilize it for energy. The extra unutilized sugar acts like poison for the whole body affecting every organ especially the eyes, heart, kidney and brain. Retina needs a lot of oxygen and has plenty of blood vessels, so it gets affected and the condition is known as DIABETIC RETINOPATHY. It results in loss of vision.

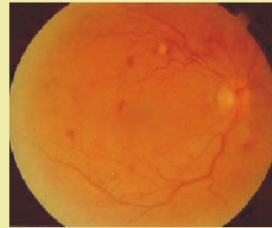
**STAGES OF DIABETIC RETINOPATHY:-**

There are mainly 2 stages of diabetic retinopathy;  
 1. Background or Non Proliferative Diabetic Retinopathy (NPDR) or  
 2. Proliferative Diabetic Retinopathy (PDR).  
 Diabetic Maculopathy (DM) can be present in

**Non Proliferative Diabetic Retinopathy (NPDR)**

This is the earliest stage where blood vessels in the retina leak fluid, sometimes fat and blood into retinal tissue.

This results in development of Micro aneurysms, edema (swelling) and hard exudates in retina. Many people with NPDR have normal vision and the treatment consists of STRICT CONTROL of Diabetes and associated systemic illnesses. Periodic follow up examinations every year is very important



Photograph showing Retinal haemorrhages & microaneurysm in a patient of NPDR

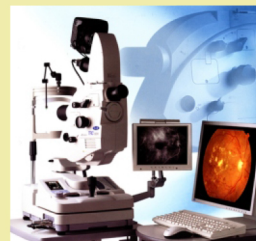
**DIABETIC MACULOPATHY (DM)**

Macular Edema: Due to the fluid leaked from the capillaries, there is a swelling at the macula which leads to impairment of vision from mild to severe degrees.  
 Macular Ischemia occurs when small blood vessels (capillaries) close at macula which leads to drop in vision.

**INVESTIGATIONS:-**

FFA (Fundus Fluoresceine Angiography):- Fluoresceine dye is injected in the vein and photographs are taken of both retina with FUNDUS CAMERA. It shows the structure of retinal vessels, leakages and perfusion status of retina.

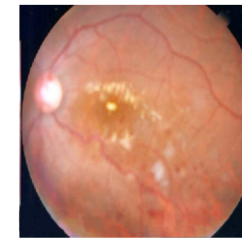
(TOPCON FUNDUS CAMERA TRC 50 DXIA) (ZEISS STRATUS OCT)



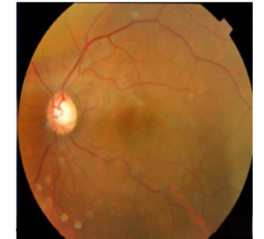OCT (Optical Coherence Tomography) provides additional information regarding thickness and structure of macula and relationship of vitreous fluid to macula.

**TREATMENT OF DIABETIC MACULOPATHY:-**

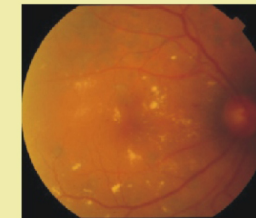
1.)In addition to proper management of diabetes, treatment consists of laser treatment to macula and/ or intravitreal injection of steroid or anti-VEGF drugs like Avastin, Macugen or Lucentis.  
 2.)Occasionally, vitreous surgery may help in treatment.



PRE STEROID INJECTION

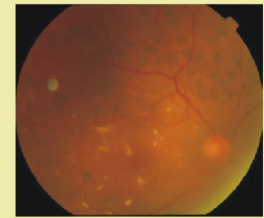


POST STEROID INJECTION



PRE LASER TREATMENT

Shows Diabetic Maculopathy with exudates



POST LASER TREATMENT

Shows treated Diabetic Maculopathy with less exudates after laser treatment

**PROLIFERATIVE DIABETIC RETINOPATHY (PDR):-**

Closure of multiple capillaries (tiny blood vessels) leads to growth of abnormal new blood vessels on the surface of retina and/ or optic nerve (neovascularisation). These new vessels are weak and bleed easily, leading to vitreous hemorrhage. They are often accompanied by scar tissue which can lead to tractional retinal detachment. When the